

# Harvest and Application of Bone Marrow Aspirate Concentrate From the Ilium during hip arthroscopy for Acetabular Labral Repair is Safe and Reliable

**Brandon J. Allen, BA**

On Behalf of the Dr. Scott Martin Research Team

Co-Authors: **Martin SD<sup>1</sup>**, Mun JS<sup>1</sup>, Chenna SS<sup>1</sup>, Allen BJ<sup>1</sup>, Poutre RL<sup>1</sup>, Gillinov SM<sup>1</sup>, Siddiq B<sup>1</sup>, Dowley KS<sup>1</sup>, Cherian NJ<sup>2</sup>, Eberlin CT<sup>3</sup>

<sup>1</sup>Sports Medicine, Department of Orthopaedic Surgery, Massachusetts General Hospital, Boston, Massachusetts, U.S.A.

<sup>2</sup>Department of Orthopaedic Surgery, University of Nebraska, Omaha, NE, U.S.A.

<sup>3</sup>Department of Orthopedics and Rehabilitation, University of Iowa, Iowa City, IA, U.S.A.

Email of Presenting Author: [ballen15@mgh.harvard.edu](mailto:ballen15@mgh.harvard.edu)



# DISCLOSURES

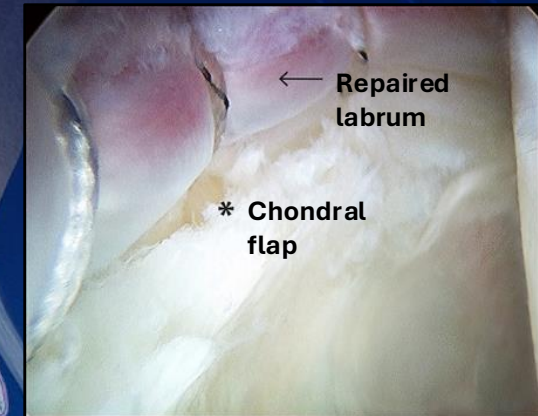
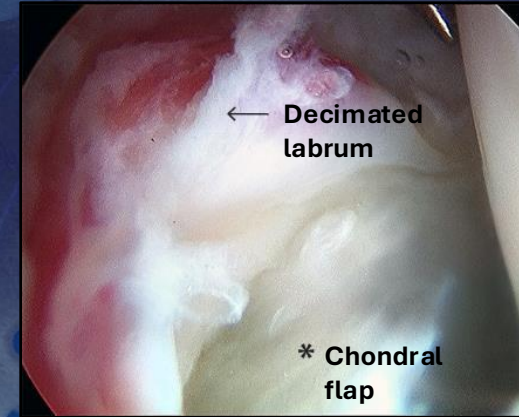
- *Research Support provided by:*
- ***The Conine Family Fund for Joint Preservation***
- I (and/or my co-authors) have nothing to disclose directly related to this talk.
- I have no conflicts.



# BACKGROUND

- **Bone marrow aspirate concentrate (BMAC)**
  - **Shown improved mid-term functional outcomes**
    - **With moderate cartilage damage**
  - **Complication rates of harvest and application of BMAC**
    - **Understudied**
- **Study Aim**
- Evaluate the safety and reliability of **BMAC harvesting** and **application** from the body of the ilium during hip arthroscopy for acetabular labral repair.

## Arthroscopic Labral Repair



# METHODS

- Retrospective chart review
  - All patients who underwent hip arthroscopy with BMAC
- Harvest of injection components
  - Bone marrow aspirate (BMA)
    - Centrifuged for BMAC
  - Platelet rich plasma (PRP)
  - Platelet poor plasma (PPP)
- Evaluated for minor and major post-operative complications
  - Minor
    - Asymptomatic heterotopic ossification
    - Transient neurapraxia
    - Trochanteric bursitis
  - Major
    - Infection
    - Deep vein thrombosis
    - Pulmonary embolism
    - Avascular necrosis
    - Dislocation
    - Instability
    - Femoral neck fracture

# RESULTS

- 331 Patients were reviewed
  - 127 female
  - Mean age:  $31.2 \pm 9.5$  years
  - Mean BMI:  $25.7 \pm 4.1$  kg/m<sup>2</sup>

Variable (N=331)	Mean±SD or Count (%)
Gender	
Male	204 (61.6)
Female	127 (38.4)
Age (years)	31.2±9.5
Tönnis Grade	
0	178 (52.4)
1	140 (41.2)
2	14 (4.1)
3	1 (<1)
Dysplasia	
Yes	14 (4.1)
No	318 (93.5)
Coxa Profunda	
Yes	104 (30.6)
No	229 (67.4)
Protrusio Acetabuli	
Yes	11 (3.2)
No	322 (94.8)
Os Acetabuli	
Yes	39 (11.5)
No	294 (86.5)

Table 1. Intraoperative and Demographic Variables



# RESULTS

## • Major and Minor complications

- 24 (7.3%) patients experience minor complications
- 2 (<1%) patients experienced major complications

Complications	Count (%)
Deep Vein Thrombosis	2 (<1)
Asymptomatic Heterotopic Ossification	14 (4)
Transient Neurapraxia	9 (2.7)
Trochanteric Bursitis	1 (<1)

Table 2. Major and Minor Complications

Variables	mean±SD
Estimated Blood Loss (mL)	26.7±7.1
Traction Time (min)	74.0±7.2
Operative Time (min)	127.3±32.8
Bone Marrow Aspirate (cc)	106.5±25.4

Table 3. Intraoperative Time and Volume



# CONCLUSIONS

- **Reliable and safe harvest site**
  - **Low complication rates**
- **Minimized donor site morbidity**
  - **Minimal blood loss**
  - **Low traction time**
  - **Low operative time**
  - **Substantial concentration of connective tissue progenitor cells**

# THANK YOU

Nicole Wojt ©2024

Massachusetts General Hospital

